



PATIENT

Lily Cicero

SPECIES

Feline

BREED

DSH

SEX

Female Spayed

AGE

10.8 years

WEIGHT

11.2lbs

INTERPRETED BY

Maggie Machen Lamy,
DVM, DACVIM
(Cardiology)

IMAGING PERFORMED BY

T. Tenorio, DVM

HOSPITAL NAME

Wauwatosa Vet

REFERRING VET

Dr. Binor

INVOICE

23987

DATE

5/3/22

PRESENTING CLINICAL SIGNS

History: History of eosinophilic enteritis for several years. She needs a dental prophy--has a resorptive lesion. Heart auscultation indicated a grade II/VI heart murmur. BNP was normal. Currently on steroids for eosinophilic gastroenteritis. Assess prior to anesthesia.

RADIOGRAPHIC FINDINGS *NOTE: Images submitted for supplemental cardiac information only. Normal cardiac silhouette. No obvious evidence of CHF.

ECHOCARDIOGRAM FINDINGS

2D, m-mode, color flow and doppler imaging is available. The left ventricular wall is irregular with a focal septal thickening and the remainder measuring normal. There is a mildly hyperechoic endocardium consistent with fibrosis. The papillary muscles are mildly hypertrophied. The left atrium is normal in size. The right atrium is normal in size. Mild SAM is appreciated with mild MR. No TR. Blood flow through the RVOT is normal. The blood flow through the LVOT is normal on doppler; however, an intermittent LVOTO is suspected on color flow and 2D imaging. No pleural or pericardial effusion seen. No obvious cardiac tumors.

CARDIAC CHART

FELINE CARDIAC PARAMETERS	BODY WEIGHT (kg)	HR (BPM)	IVSd (cm) <small>(Moise, Pipers)</small>	LVIDd (cm) <small>(Moise, Pipers)</small>	LVWd (cm) <small>(Moise, Pipers)</small>	FS (%)	EF (%)
NORMAL PARAMETER	-----	150-240	0.35-0.55	<2 (mean 1.5)	3.5-0.55	35-67	80-100
PATIENT	5.1	NM	0.44	1.53	0.46	44	80
FELINE CARDIAC PARAMETERS	LA/AO <small>(Boon)</small>	LA/AO HEART BASE (Swe) <small>(Abbott)</small>	LA 2D short axis Base view (cm) <small>(Abbott)</small>		LVOT VEL (m/s)	RVOT VEL (m/s)	E max (m/s)
NORMAL	<1.5	<1.3	<1.2		<1.6	<1.3	<0.9
PATIENT	1.5	1.2	1.2		1.9	1.3	NM
<p><i>*Note: All measurements based upon multi-modal images and methods. An average value is reported.</i> Adapted from June Boon, Veterinary Echocardiography, 1998 Abbott J & MacLean H JVIM 2006;20: 111-119, Moise et al. Am J Vet Res 47:1476, 1986. Pipers et al. Am J Vet Res 40:882, 1979.</p>							

INTERPRETATION OF THE FINDINGS & FURTHER RECOMMENDATIONS

The primary abnormality identified is focal LV hypertrophy in addition to papillary muscle hypertrophy, which may be indicative of early hypertrophic disease or may simply represent a normal variant. The LA is normal which would indicate clinical stability. Serial echocardiography will be necessary to determine progression and clinical significance. Additionally, the murmur is due to a mild LVOT obstruction with secondary MR, which appears intermittent and does not warrant therapy. No additional issues are identified.

No obvious pulmonary or mediastinal abnormalities are visualized; however, a thoracic evaluation is outside the scope of an echocardiogram. If concern persists, consider a Radiologist review of the films, thoracic scans, etc.



PATIENT

Lily Cicero

SPECIES

Feline

BREED

DSH

SEX

Female Spayed

AGE

10.8 years

WEIGHT

11.2lbs

INTERPRETED BY

Maggie Machen Lamy,
DVM, DACVIM
(Cardiology)

IMAGING PERFORMED BY

T. Tenorio, DVM

HOSPITAL NAME

Wauwatosa Vet

REFERRING VET

Dr. Binor

INVOICE

23987

DATE

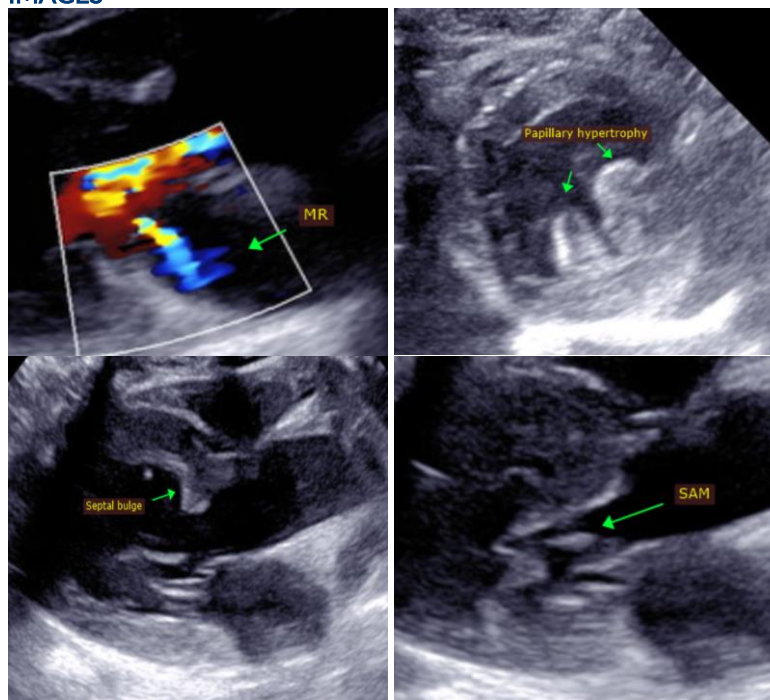
5/3/22

Anesthetic risk is considered mild, however judicious IV fluid rates are advised to avoid fluid overload. Additionally, drugs that stimulate heart rate should be avoided unless clinically necessary (glycopyrrolate, atropine). Avoid vasodilators as this may worsen the obstruction. A reasonable protocol includes opioid/benzodiazepine premedication, propofol induction, isoflurane maintenance. Additionally, steroids should be used with caution on older cats, as even a 'normal' geriatric heart can develop evidence of intolerance and fluid retention.

Monitor for any development of clinical signs, including labored breathing or signs of a blood clot (paralysis, neurologic change). Prognosis is guarded prior to assessing for progression.

A recheck echocardiogram is recommended in 6-12 months to screen for any evidence of progression.

IMAGES



The information and recommendations provided are based on the images presented by the referring veterinarian. No evaluation can be communicated regarding pathology that was not visible in the image/video clips provided.

Thank you for this referral. This report was generated using transcription software, and minor dictation errors may be present. If the clinical or image interpretation does not parallel your findings or if I can be of any further assistance, please contact me.

Maggie Machen Lamy, DVM
Diplomate of the American College of Veterinary Internal Medicine (Cardiology)
info@sonopath.com